

## MUMMIES UNDER THE WADI. PRELIMINARY STUDY OF A BURIAL DEPOSIT IN THEBAN TOMB 209 (SOUTH ASASIF, EGYPT)

Jared Carballo<sup>1</sup> and Miguel Ángel Molinero Polo<sup>2</sup>

<sup>1</sup> UDI de Prehistoria, Arqueología e Historia Antigua  
Facultad de Humanidades. Universidad de La Laguna  
38200 San Cristóbal de La Laguna, Santa Cruz de Tenerife, España  
jcarbalp@ull.edu.es

<sup>2</sup> UDI de Prehistoria, Arqueología e Historia Antigua  
Facultad de Humanidades. Universidad de La Laguna  
38200 San Cristóbal de La Laguna, Santa Cruz de Tenerife, España  
mmolipol@ull.edu.es

---

CARBALLO, J. AND MOLINERO-POLO, M.A. (2021). Mummies under the Wadi. Preliminary Study of a Burial Deposit in Theban Tomb 209 (South Asasif, Egypt). *Canarias Arqueológica*, 22: 615-628.  
<http://doi.org/10.31939/canarq/2021.22.52>

**Abstract.** Theban Tomb 209 (South Asasif, West Bank, Luxor), was built during the Twenty-Fifth Dynasty, probably during the second half of the 8<sup>th</sup> century BCE. It was reused as a burial place during Persian and Ptolemaic Periods, and was filled by sediments carried by floodwaters that passed through the Wadi Hatasun until it was completely covered in the following centuries. A preliminary study of three mummies discovered during the work of the Archaeological

Mission of the University of La Laguna is presented in this paper. They were uncovered during the 2018 season, in one of the side chambers of the tomb, being the upper level of a larger mortuary deposit whose excavation is still in progress. These preliminary studies were undertaken from the perspective of osteoarchaeology, which combines disciplines such as physical anthropology and funerary archaeology in order to reconstruct life and death in ancient populations.

**Keywords.** Physical Anthropology, Mummy Studies, Funerary Archaeology, Ptolemaic Period, Ancient Egypt.

Theban Tomb 209 was built for a Twenty-Fifth Dynasty Nubian official called Nisemro, probably during the second half of the 8<sup>th</sup> century BCE. The tomb is in an unusual location, as it was constructed on the slope of the Wadi Hatasun, in the area of the necropolis known as South Asasif that extends to the west of Ramesses II's Mansion of Millions of Years, now commonly called the *Ramesseum* (Fig. 1).

Three centuries after the earliest burials, which were probably those of the owner and members of his family, the tomb was reopened and reused as a cultic place. Funerary ceremonies were celebrated in every underground chamber of the tomb, as well as in the external building, for several centuries from the last decades of the first Persian Period to the Ptolemaic Dynasty (Barahona, 2018: 21–26).

After it was reopened, the tomb began to be periodically flooded by rainwater channelled through the bed of the wadi. The sediments deposited by these events eventually filled the inner chambers and prompted the collapse of the external buildings. Rubbish dumped from the nearby modern village of Hurubāt later covered the remains of the site (Molinero *et al.*, 2017: 246).

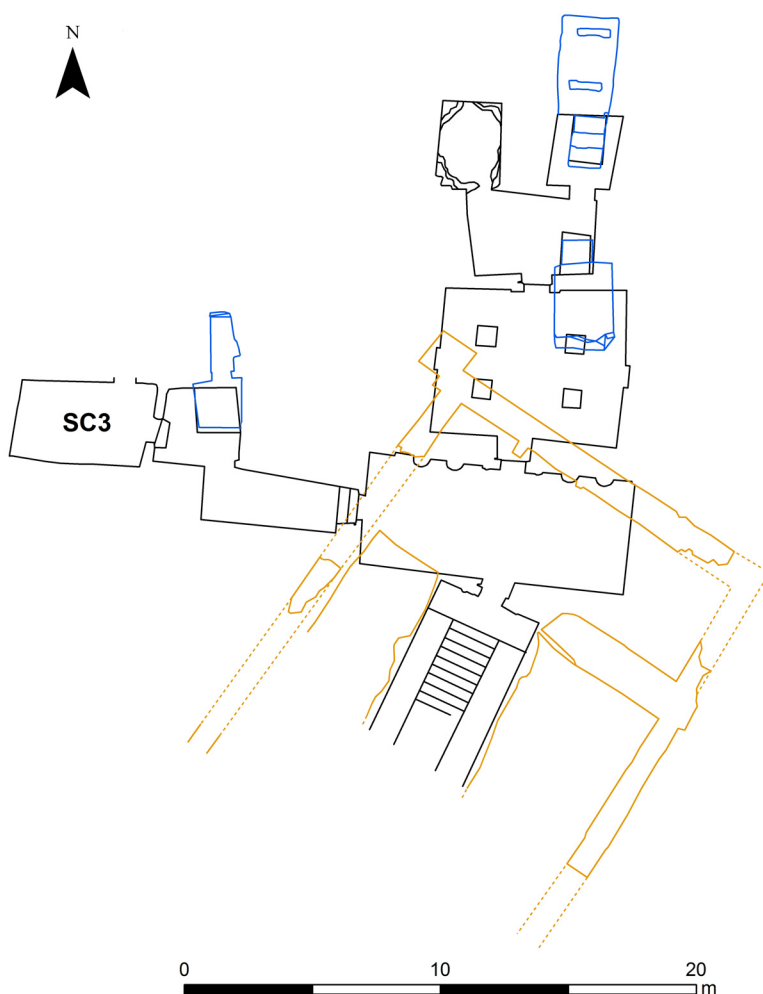
The Archaeological Mission of the University of La Laguna is currently excavating TT 209. The discovery in one of the side chambers of a burial deposit has allowed us to identify at least some of those who received the offerings, evidence for which has been found on the floor of every chamber of the tomb.



**Fig. 1.** Wadi Hatasun seen from the east (Photograph: J.M. Barrios Mufrege).

## I. A BURIAL DEPOSIT BETWEEN FLOODS: THE CONTEXT OF SIDE CHAMBER 3

After the excavation of the main-north-south-axis of TT 209, work in recent seasons has focused on a perpendicular axis that opens from the transverse hall (Fig. 2). The presence of small, individual side chambers is not uncommon in Theban tombs (see the plans in Eigner, 1984, vol. 2), but those in the tomb of Nisemro are




**Fig. 2.** Plan of TT 209 at the end of the 2019 season (Drawing: S. Pou Hernández).

noteworthy. The first is a long corridor that runs toward the west, followed by a square chamber with a broad shaft and finally by another large rectangular space ( $5.10 \times 3.15$  m), now called Side Chamber 3 (SC3). This series of chambers was not disturbed by the Egyptologists and local villagers who entered the tomb following its discovery at the beginning of the 20<sup>th</sup> century, which means that the Canarian mission uncovered their contents as they were deposited in Antiquity, either by human agents or by floodwaters.

During the 2018 season, a burial deposit with three mummies was found in the southeastern corner of SC3, lying over a large accumulation of limestone blocks and dark silts (Fig. 3). In order to reveal these remains, it was necessary to remove several layers of the compact sediments.

According to descriptions of similar sedimentary features studied in other rainwater deposits (Benito *et al.*, 2003: 117-119), it seems that the silts that covered the TT 209 mummies were brought in by a low intensity flood. There is nevertheless evidence that indicates that the human remains closer to the



**Fig. 3.** SC3, at the level of the upper mummies (Ortophotograph: S. Pou Hernández).

entrance were greatly affected by the floods. Some of the lower limbs from the individuals that were in the south-east corner have disappeared, and associated material seems to have been dispersed into secondary positions. Observations in other areas of the tomb show that high-intensity flood events carved channels along the walls, and this implies a corresponding dispersion of materials. In addition, both bones and bandages were in a poor state of preservation due to repeated floods both in Antiquity and after the tomb was reopened in the 20<sup>th</sup> century.

It is also important to relate that only two of the mummified individuals (Mummies 1 and 2) showed evidence of bandages around their bodies. The third (Mummy 3), located at a lower level, only retained a small layer of bandage on the parietal bone.

The stratigraphic context shows that Mummy 3 was buried before the other two, who were placed on top. In addition, some fragmented human bones (Individual 4) appear to have been accumulated in the south-east corner, in a secondary position. This could mean that remains from an earlier deposition were pushed aside in order to make space for the later burials.

The presence of earlier burials was confirmed by the discovery of other mummies below these four bodies during the 2019 season. Their anthropological study is still ongoing.

## 2. RECONSTRUCTING LIFE FROM DEATH: THE ANTHROPOLOGICAL ANALYSIS

Osteoarchaeology is an important tool from which to approach human remains because it acts as an intersection between biology and culture: patterns of daily life, social status, and gender can be traced from bones (Sofaer, 2006: 89-105). The TT 209 deposit has thus been studied from an osteoarchaeological perspective, using techniques from disciplines such as physical anthropology, funerary archaeology and mummy studies.

Due to the poorly preservation of the bandages, it was possible to study some morphometric traits from the exposed bony areas of these mummies (Fig. 4). Standard methods, including the fusion of cranial sutures (Meindl & Lovejoy, 1985: 63), the morphological features of the crania (Buikstra & Ubelaker, 1994: 20; Spradley & Jantz, 2011: 291-292), and the length of long bones (Raxter *et al.*, 2008: 150), were used during this anthropological analysis.





**Fig. 4.** One of the Ptolemaic vessels found close to the mummies (Photograph: M.A. Molinero Polo).

The data collected during fieldwork showed that each of the three mummies had a different osteobiography. The first body to be buried (Mummy 3), was probably a male between 30 and 40 years old. The other two, deposited later, were possibly a male (Mummy 1) and a female (Mummy 2), both between 60 and 69 years of age. The latter individuals seem to have lived longer than most of the population, since the average life expectancy in Roman Egypt – the closest comparable data to when these people were alive – was around 22 to 25 years old (Scheidel, 2001: 118). The biological profile of Mummy 3 would be more consistent with this value.

The mummies differed somewhat in stature. The younger male was around 1.60 m tall, while the elderly male was a bit taller, at 1.66 m. Both seem to have been typical of the population, as the computed male average for Ancient Egypt was 1.67 m (Zakrzewski, 2003: 224). Such values would have varied according to changing socio-economic circumstances since the Predynastic Period, and it is pos-

sible that body sizes decreased towards the end of the Dynastic Period due to poor nutrition and genetic conditions (Eladany, 2011: 287–288).

The exposed bony areas have allowed us to investigate the daily life of these individuals. Using biomechanical methodologies (Santana, 2011: 203–256), it has been possible to obtain some data about their physical activity patterns. For example, a high level of robustness was observed in the *M. biceps brachii*, *M. quadriceps* and *M. tibialis anterior* muscles of the older male (Mummy 1), so he could have undertaken daily activities linked to high mobility and heavy lifting. Mummy 3, however, showed almost no entheseal changes in his lower limbs, but robust attachments in his *M. extensor digitorum* and *M. flexor carpi ulnaris*. This could mean that the younger male led a sedentary lifestyle and his profession may have required a certain amount of capability with the fingers and wrists.

Even though some individuals, such as the elderly female (Mummy 2), had lost some teeth both *antemortem* and *postmortem*, it was possible to use techniques of dental anthropology (Irish & Scott, 2016: 413–432) to make some assessments. An advanced occlusal attrition was observed in each of the three individuals, which was the most common dental condition in the ancient Egyptian population. This probably points more towards a coarse diet, such as one that included sand accidentally baked into bread, than a nutritional deficiency (Leek, 1972: 291).

### 3. DEFINING THE AFTERLIFE: MUMMIFICATION, BURIAL CUSTOMS AND ITS CHRONOLOGY

Along with anthropological information, field studies of the deposit have offered data concerning the mummification process. The state of preservation of the bodies in SC3 was affected by post-depositional process such as floods, but it has still been possible to study some specific features of mummification and burial customs.

For example, it has been possible to deduce an approximate chronology for the burial deposit due to the goods that were found around the mummies. Four large pottery vessels (three jars and one dish) match Ptolemaic typologies (Budka, 2010: 42), and could have been used to place food offerings during ceremonies in honor of the deceased (Fig. 5). Around 50 reddish clay ushebtis (category C1.VIII A1.1 according to Schneider) were found in the same stratigraphic unit (Schneider, 1977: 219–225; Makowska, 2005: 13).

These items were placed as offerings for these three mummies, which had been deposited, with their heads towards the west, and in the classic supine position



**Fig. 5.** Composition of bone features from the funerary deposit (Photographs: M.A. Molinero Polo).

with the arms crossed over the chest (Fig. 6). This type of disposition, with the right arm over the left, has been interpreted as an imitation of Osiris and although it was originally a sign of kingship, during the Ptolemaic Period it came to be practiced even among those who underwent the most basic mummification (Ikram, 2015: 64-71).

During the processes of excavation and documentation process, it was observed that the three mummies were covered with between one and three layers of linen bandage, according to the anatomic region. The heads only had a single layer, but the lower limbs had two over each leg, and one extra layer to join them together. The mummy bandages seem to have been spirally wound around the torso and extremities.

As with the bones, the bandages were extremely fragile, but their black color meant that it was easy to detect their presence within the compact sediments.





**Fig. 6.** Mummy I with its arms crossed over its chest (Photograph: M.A. Molinero Polo).


The blackening of the bandages could have been caused by a mixture of resins and oils, or by post-depositional conditions such as floods, but may also have been due to the humidity (Fig. 7). The reason why fabrics were preserved while human soft tissues may be due to coniferous resins and oils (principally from a *Juniperus* sp. such as a cedar) that were poured over the mummified bodies, because the embalmers had experience that such materials helped in the preservation process. Recent archaeometric analyses of ancient Egyptian bandages have shown that a mixture of resins and oils can create a polymeric barrier that impedes the presence of microorganisms (Nicholson & Shaw, 2000: 372–390; Abdel-Maksoud & El-Amin, 2011: 134–137).

One of the most curious aspects of this archaeological context was that the head of Mummy I was found separated from the rest of its body (Fig. 8); there was a gap of 1 cm between the 6<sup>th</sup> and the 7<sup>th</sup> cervical vertebrae of the neck. A plausible explanation, observed in several other examples from the Ptolemaic



**Fig. 7.** Close-up of Mummy 2 with blackened bandages (Photograph: J. Carballo Pérez).





**Fig. 8.** Detail of Mummy I's head, with its neck separated from its body (Photograph: M.A. Molinero Polo).

Period, is that excerebration was sometimes practiced from the *foramen magnum*, by cutting off the head instead of breaking the ethmoid bone (Ikram, 2015: 71). Some authors have noted that this feature may have been the result of poor mummification practice, which caused the head to separate from the body. The presence of wooden sticks (such as the ribs of palm fronds) to support the mummified head has been reported (Eladany, 2011: 314–315), but if something of this nature was placed inside Mummy I's neck then it has not been preserved. Any such pole might have been dislodged by floodwaters, which might also have displaced the head.

The ethmoids were intact in the three Ptolemaic individuals from TT 209, but it is important to note that no other evidence of evisceration has been found. This is not exceptional because evisceration became less common in the mummification process after the Late Period (Ikram, 2015: 70).

The osteoarchaeological field analysis performed in TT 209 has produced some interesting results. The upper level of the flood sediments inside SC3 contained a burial deposit of three individuals: an elderly man, an elderly woman, and an adult man, each with different daily life patterns but of similar stature. Anthropological analysis has provided hints about their lives and about certain aspects of the mummification process during the Ptolemaic Period. The discovery of these mummies also provides an explanation for the presence of funerary cult offerings, which have been discovered in the underground chambers of TT 209 since the beginning of the current archaeological project. They would have been deposited during ceremonies dedicated to these deceased individuals, and to the other mummies further below.

## BIBLIOGRAPHY

ABDEL-MAKSoud, G., & EL-AMIN, A.-R. (2011). A Review on the Materials used during the Mummification Processes in Ancient Egypt. *Mediterranean Archaeology and Archaeometry* 11 (2): 129-150.

BARAHONA-MENDIETA, Z. (2017). Estudio preliminar de la cerámica procedente de las excavaciones en la TT 209, Luxor, Egipto. *Trabajos de Egiptología* 8: 13-30.

BENITO, G. SÁNCHEZ-MOYA, Y. & SOPEÑA, A. (2003). Sedimentology of high-stage flood deposits of the Tagus River, Central Spain. *Sedimentary Geology* 157: 107-132.

BUDKA, J. (2010). The use of pottery in funerary contexts during the Lybian and Late Period. In L. Bares, F. Coppens, K. Smoláriková (eds.), *Egypt in Transition. Social and Religious Development of Egypt in the First Millennium BCE. Proceedings of an International Conference. Prague, September 1-4, 2009*. Prague: Charles University: 22-72.

BUIKSTRA, J.E. & UBELAKER, D.H. (1994), *Standards for Data Collection from Human Skeletal Remains. Proceedings of a Seminar at the Field Museum of Natural History*. Arkansas Archeological Survey Research Series 44. Fayetteville: Arkansas Archeological Survey.

EIGNER, D. (1984). *Die monumentalen Grabbauten der Spätzeit in der thebanischen Nekropole*. Wien: Verlag der Österreichischen Akademie der Wissenschaften.

ELADANY, A.H. (2011). *A study of a selected group of Third Intermediate Period mummies in the British Museum*. Manchester: KNH Centre for Biomedical Egyptology.

IRISH, J.D. & SCOTT, G.R. (2016). *A Companion to Dental Anthropology*. Blackwell Companions to Anthropology 39. Sussex: Wiley Blackwell.

IKRAM, S. (2015). *Death and Burial in Ancient Egypt*. Cairo: The American University in Cairo Press.

LEEK, F.F. (1972). Bite, Attrition and Associated Oral Conditions as Seen in Ancient Egyptian Skulls. *Journal of Human Evolution* 1: 289-295.

MAKOWSKA, A. (2015). Ushebtis of the Third Intermediate Period from the Chapel of Hatshepsut in the Queen's Temple at Deir el-Bahari. *Polish Archaeology in the Mediterranean* 24/2: 137-160.

MEINDL, R.S. & LOVEJOY, C.O. (1985). Ectocranial Suture Closure: A Revised Method for the Determination of Skeletal Age at Death Based on the Lateral-Anterior. *American Journal of Physical Anthropology* 68: 57-66.

MOLINERO-POLO, M.Á., HERNÁNDEZ-GÓMEZ, C.M., MOHAMED-ALI, H., BAKHIT-ABD-EL-HAFEZ, S., MÉNDEZ-RODRÍGUEZ, D.M., GUERRA-LIBRERO-FERNÁNDEZ, F., GARCÍA-ÁVILA, J.C., BARAHONA-MENDIETA, Z., BARRIOS-MUFREGE, J.M., DÍAZ-IGLESIAS-LLANOS, L., COLL-TABANERA, P. (2017). The Courtyard of TT 209 (Areas C1 and C2) Seasons 2012 to 2014. *Trabajos de Egiptología* 8: 247-269.

RAXTER, M.H., RUFF, C.B., AZAB, A., ERFAN, M., SOLIMAN, M., & EL-SAWAF, A. (2008). Stature Estimation in Ancient Egyptians: A New Technique Based on Anatomical Reconstruction of Stature. *American Journal of Physical Anthropology* 155: 147-155.

SANTANA-CABRERA, J.A. (2011). *El Trabajo Fossilizado: Patrón cotidiano de actividad física y organización social del trabajo en la Gran Canaria Prehispánica*. Universidad de Las Palmas de Gran Canaria.

SCHEIDEL, W. (2001). *Death on the Nile. Disease and the Demography of Roman Egypt*. Leiden, Boston, Köln: E.J. Brill.

SCHNEIDER, H.D. (1977). *Shabtis. An Introduction to the History of Ancient Egyptian Funerary Statuettes with a Catalogue of the Collection of Shabtis in the National Museum of Antiquities at Leiden*. Leiden: Rijksmuseum van Oudheden.

SOFAER, J.R. (2006). *The Body as Material Culture: A Theoretical Osteoarchaeology*. Cambridge: Cambridge University Press.



SPRADLEY, M.K. & JANTZ, R.L. (2011). Sex Estimation in Forensic Anthropology: Skull Versus Postcranial Elements. *Journal of Forensic Sciences*, 56, 289-296.

TAYLOR, R.P. (2000). *Death and the Afterlife: A Cultural Encyclopedia*. Michigan: ABC-CLIO.

ZAKRZEWSKI, S.R. (2003). Variation in ancient Egyptian stature and body proportions. *American Journal of Physical Anthropology* 121(3): 219-229.