

A POSSIBLE CASE OF PALMAR FIBROMATOSIS IN A 1ST-MILLENNIUM-BC MUMMY FROM THE ASSASSIF NECROPOLIS, LUXOR, EGYPT

Milton Núñez¹, Joaquín Baxarias², Rosa Dinarés³,
Valerie Fontaine⁴, and Elena Garcia-Guixé⁵

¹ Archaeology, PB 8000, FI-90014 Oulu University, nunez.milton@gmail.com

² Centre Médical Vermont, Voie de Gex 11, 1218 Gèneve, jbaxarias@gmail.com

³ Hospital General de Catalunya, 08195 Sant Cugat del Vallès, rdinares@gmail.com

⁴ Centre Médical /Physio, Voie de Gex 11, 1218 Gèneve, valfon66@gmail.com

⁵ Reprogenetics, Carrer de Tuset, 23, 08006 Barcelona, elegagui@gmail.com

NUÑEZ, M.; BAXARIAS, J.; DINARÈS, R.; FONTAINE, V. AND GARCIA-GUIXÉ, E. (2021). A possible case of palmar fibromatosis in a 1st millennium-BC mummy from the Assassif necropolis, Luxor, Egypt. *Canarias Arqueológica*, 22: 469-482. <http://doi.org/10.31939/canarq/2021.22.40>

Abstract. As members of the anthropological unit of the Monthemhat Project (2007-2009), we had the opportunity to examine dozens mummified individuals, including a mature man that had lived in Luxor in the earlier half of the 1st millennium BC. His left hand presented a deformation consistent with palmar fibromatosis. This diagnosis was chosen even if it seemed then somewhat out of place. The geographical distribution of palmar fibromatosis has led to the idea that the

disease has Nordic origins and that it had been spread by Vikings, hence “Viking disease”, but the ailment has been reported recently from areas lacking Nordic ancestry. In any event, if the Theban man had indeed suffered from palmar fibromatosis, then we are dealing with the earliest known case. That would push the occurrence of the disease back by at least 1500 years and place its origins geographically far from its assumed Nordic associations.

Keywords. 1st millennium BC. Egypt. Mummified mature male. Palmar fibromatosis.

INTRODUCTION

During 2007-2009 we had the privilege of participating in the Monthemhat Project, a small multinational project partly supported by private Spanish funds and aimed to restore the tomb of Monthemhat in Luxor; ancient Thebes. Monthemhat (c.700-650 BC) was a member of a powerful priest elite family and carried the titles of Major of Thebes, Governor of Upper Egypt and Fourth Prophet of Amon, in ascending order of importance. Accordingly, he built a monumental tomb, which is one of the largest in all Luxor. The tomb, known as TT-34, lies in the Assasif necropolis, in the Valley of the Nobles, c.300 m from the Temple of Hatshepsut (Lam. I). Unfortunately, TT-34 had been badly plundered, and fire had reduced the mummified remains of some 300 individuals to mere bones. (Gomaa & Martínez Babón 2007; Illarregui & Rius 2010; Baxarias et al. 2011).



Lam. I. The Assasif necropolis at the edge of the fertile green zone flanking the Nile, viewed from the southwest. The left arrow points to the large Monthemhat's tomb complex (TT-34) and the right one to the location of Cache 4. The parking lot by TT-34 is for busses of tourists visiting the Hatshepsut's Temple complex c.300 m away.

Luckily, some sarcophagi and mummies had been taken out of the tomb in the 1950s. The discovery of an old photograph showing the removal of some sarcophagi from TT-34 prompted a search, which was finally rewarded when our Egyptian colleagues led us to the so-called Cache 4 in the 2009 field season (Lam. I). It was a nameless empty tomb currently used for storage, where we found a chamber packed with 18 mummies (Garcia-Guixé *et al.* 2010; Núñez *et al.* 2011).

At the time, it was unclear whether any of the mummies came from TT-34 or not. Dr Zacaria Goneim, who had been working in TT-34, had died suddenly in 1959 without leaving proper records. Nevertheless, some photographs showed Goneim in the TT-34 courtyard inspecting some mummies, two of which could be positively identified with Mummies 9 and 16 in Cache 4. Admittedly, this is no guarantee that all the mummies in Cache come from TT-34, but at least the embalming procedures place them all in the 3rd Intermediate Period (1040-656/525 BC), and the linen wrappings of Mummy 16 yielded an AMS date of 976-811 cal BC (Garcia-Guixé *et al.* 2010; Núñez *et al.* 2011). All this is compatible with several generations of priest-elite ancestors being gathered by Mothemhat in his new tomb (Leclant 1961; Payraudeau 2013).

While examining the Cache 4 mummies, V. Fontaine noticed that the left hand of Mummy 2 presented an anomaly resembling palmar fibromatosis¹ (Lam. II). This kind of deformation is often called the “benediction hand” due to similarities to the common gesture of early Christian art, though it is already present in the Sabazios cult hands found in Pompeii (79 AD), in the Augustus di Prima Porta statue from c. 15 AD, and in representations of Greek deities from 500-300 BC (Anon. 1992; Zdilla 2017; Berndt 2018). This paper deals with the pathological anomaly observed in Mummy 2.

MATERIAL AND METHODS

The mummies of Cache 4 were first examined and photographed inside the old tomb chamber, and then they were carefully taken outside for further study and photography in daylight. Finally, they were scrutinized with a digital X-ray device (Philips BV Pulsera C-arm mobile) before being returned to their storage place.

¹ The disease has many names: Palmar fibromatosis, palmar fibromas, Dupuytren's disease (DD) or contracture, contraction of palmar fascia, Viking disease, etc.

In the case of Mummy 2, the fact that the malformed hand was partially resting on the thigh made it very difficult to inspect the palmar area. It could not be lifted or rotated arm without damaging the arm, and radiology was not much help either. The best we could do was to improvise by taking “blind” camera shots into the narrow gap separating hand and thigh. A couple of photographs provided adequate views of the palmar surface.

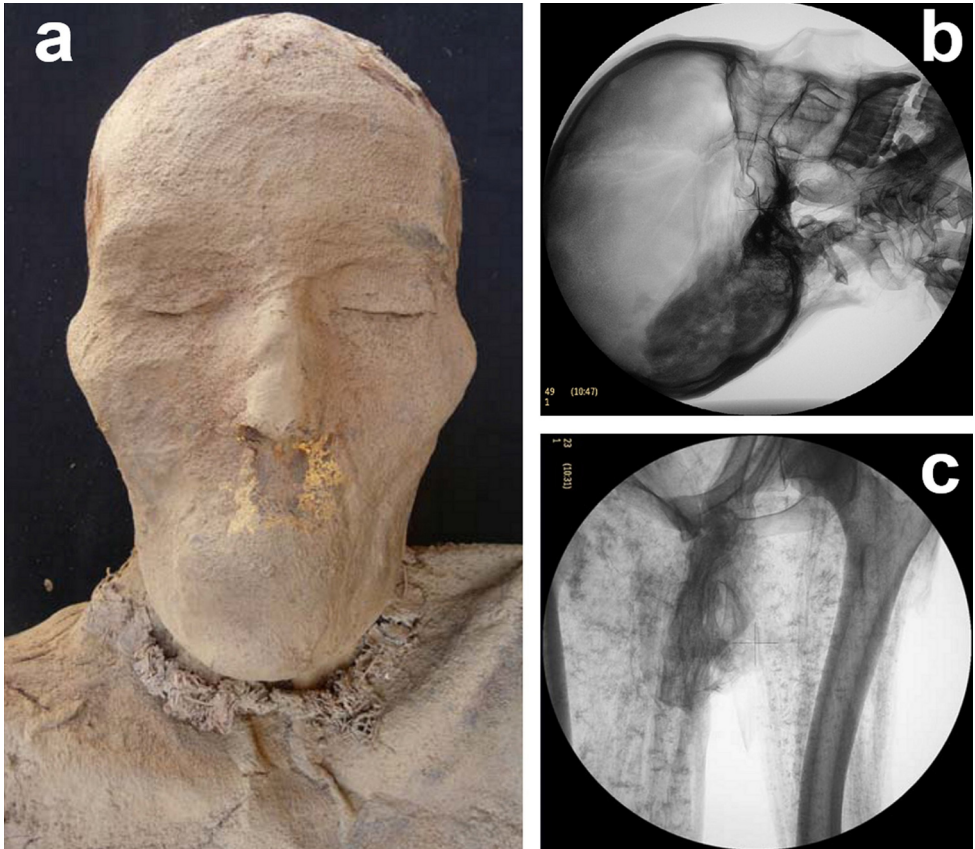
OBSERVATIONS

The wrappings of Mummy 2 had been removed by looters or researchers (Lam. II), which facilitated its anthropological examination. The individual was a mature male (40-60 years old) about 165 cm tall. The mummified body was fairly well preserved, but presented rodent damage on the posterior side. Both eyes and mouth were closed and there were remnants of reddish hair on the head and brows (Lam. IIIa). There were no signs of transnasal decerebration. The ethmoid was intact and the radiological examination revealed the desiccated brain within the cranial cavity (Lam. IIIb). No major manifestations of osteoarthritis were ob-



Lam. II. Mummy 2 and its deformed left hand with fingers 1 and 2 fully extended and fingers 4 and 5 flexed.

A POSSIBLE CASE OF PALMAR FIBROMATOSIS IN A 1ST MILLENNIUM-BC MUMMY
FROM THE ASSASSIF NECROPOLIS, LUXOR, EGYPT



Lam. III. Some details of Mummy 2: (a) The face with both mouth and eyes closed and remnants of gold foil and eye-brow hair; (b) Radiography of the cranium with the desiccated brain; (c) Radiography showing the partially calcified femoral artery.

served, but there was some calcification of the right femoral artery (Lam. IIIc) and clear Harris lines on both tibiae. Remnants of gold foil on the face point to the individual's high status, but there were no valuables goods left. (Fontaine & Garcia-Guixé 2010; Garcia-Guixé et al. 2010).

In the deformed left hand, the second (index) and third (middle) fingers are fully extended, while the fourth (ring) and fifth (pinky) ones are flexed (Lam. II). This type of deformation could be attributed to either ulnar nerve palsy or palmar fibromatosis.

DIAGNOSE

Ulnar nerve palsy is caused by an impingement of the ulnar nerve, which is usually trauma-related. Its more severe manifestations are characterized by the so-called “claw hand” condition, which commonly involves the fourth and fifth fingers. (Stewart 1987; O’Driscoll *et al.* 1991; Robertson & Saratsiotis 2003; Scott *et al.* 2015).

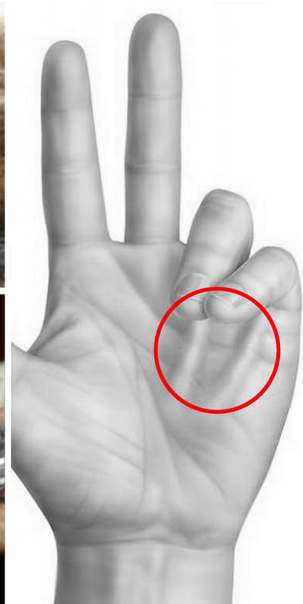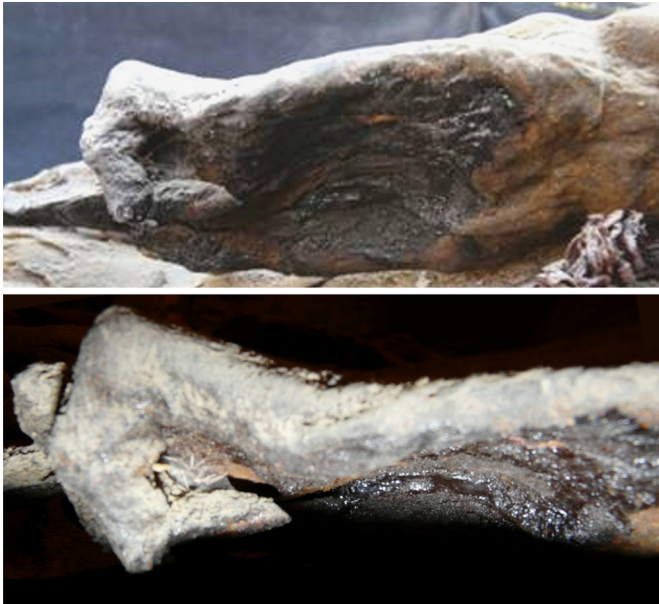Palmar fibromatosis, on the other hand, is a progressive genetic disorder characterized by the development of fibrosis in the palmar fascia. At advanced stages it causes digital flexion contractures affecting generally the fourth finger, but frequently involving also the fifth. According to medical literature, it is prevalent in elderly males of North European ancestry, but the ailment has been recently reported in populations with little or no North-European origins. (McFarlane *et al.* 1990; Hindocha *et al.* 2009; Werker *et al.* 2016).

Although the two diseases are rather different in nature (Table 1), their resulting deformations can look pretty much the same: hands with contracted fourth and fifth fingers. There is nevertheless one crucial difference that may be visible in mummified remains. We are referring to the fibrotic pads or cords characteristic of palmar fibromatosis.

Despite the difficulties in observing the palmar face of the deformed hand, we believe that the obtained photographs reveal their presence (Lam. IV). Consequently, we chose the palmar fibromatosis alternative, which is also in agreement with the individual’s age and sex.

Table 1. Ulnar nerve palsy versus palmar fibromatosis

ULNAR NERVE PALSY	PALMAR FIBROMATOSIS
Trauma related	Hereditary
Not associated with age, sex or race	Prevalent in elderly men of Nordic ascent
Due to impingement of ulnar nerve	Due to fibrosis formation in palmar fascia



Lam. IV. The two photographs on the left show the dark elongated features that have been interpreted as the fibrotic pads or chords characteristic of palmar fibromatosis, as seen in the hand illustrated on the right.

DISCUSSION

We chose the palmar fibromatosis diagnose even if at the time it seemed somewhat out of place. The geographical distribution of the disorder has led to the well-established idea of a North European origin and that it had been spread by Vikings. There are no references to the disease in Galen's or other ancient medical treatises and, admittedly, the earliest credible mentions come from descriptions in the Islandic and Orcadian sagas:

Another man high Sigurd, from the north of Shetland; he had cramped hands, so that all the fingers lay in the palms (Dasent 2012: 275).

The hands went stiff and leprous so that he could not straighten his fingers (Jakobsson & Clark 2013: 24).

The miracle cures of these ailments are respectively ascribed to Saint Magnus (†1116) and Saint Thorlak (†1198) and were first written down in the 13th century.

A possible reason for the absence of the disease in early medical treatises may have to do with its late development in elderly individuals. Low life expectancy would have excluded many from being affected (cf. Elliot 1988). It is also likely that the disease could be confused with lepra, as suggested by Thorlak's saga, or with other hand-crippling ailments associated with old age. The vague saga descriptions may or may not refer to palmar fibromatosis, but they have helped giving rise to the term "Viking disease". Possibly, the thought of descending from the glamorous Vikings serves as some sort of consolation to disease sufferers.

A survey of the recent medical literature shows that most authors accept the widespread idea of Nordic/Viking origins, for example:

There is epidemiological evidence that the disease is very common in northern Europe and populations descended from northern Europeans. The disease has a very high prevalence in Scandinavian, Scottish and Icelandic inhabitants with up to 40% of men aged over 60 having some clinical evidence of Dupuytren's. This has led to speculation of a Viking origin for the disease in the UK; a topic that frequently entertains the patient as to their possible ancestry. In populations without any direct northern European ancestry the disease is rare (Craxford & Russell 2016:139).

This comment is puzzling after calls for caution due to lack of research in "non-Scandinavian areas" (Degreef & De Smet 2010) and a series of recent reports of high prevalence of palmar fibromatosis in populations lacking Nordic ancestry like Bosnia-Herzegovina, Turkey, Israel and Japan (Zerajik & Finzen 2004; Sorene et al. 2007; Hindocha et al. 2009). Moreover, the prevalence of the disease in the actual "Viking homelands" (Norway, Sweden and Denmark) is about the same as in Mediterranean Spain and Italy (Figs. 1-2).

Nevertheless, the association of the disease with the Vikings is so well established that Slattery (2010) suggested that its presence in Japan and the Far East had to do with the Swedish Vikings' activities in the Kiev region and its subsequent occupation by the Mongols, which resulted in an eastwards displacement of slaves, troops, and the disease. However, if this sort of reasoning is acceptable, one could also propose a similar "Devil's Advocate" model based on the premise that the disease existed in Egypt 2500 years ago. Assuming it did, then palmar fibromatosis could have been spread by the Romans, who occupied both North Africa (including Egypt) and Britain. Another possibility is of course the famous/infamous Vikings, who raided along the North African and British coasts and even settled on the

A POSSIBLE CASE OF PALMAR FIBROMATOSIS IN A 1ST MILLENNIUM-BC MUMMY
FROM THE ASSASSIF NECROPOLIS, LUXOR, EGYPT

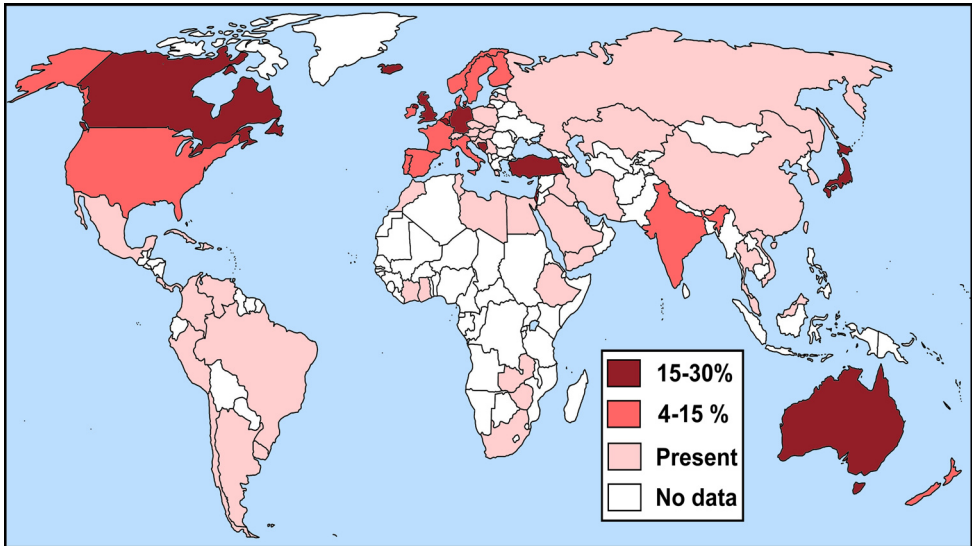


Fig. 1. Prevalence of palmar fibromatosis by country. The category “present” refers to countries where the disease occurs but lacks prevalence statistics, possibly due to low incidence. (Modified and updated from Hindocha et al. 2009; see also Fig. 2).

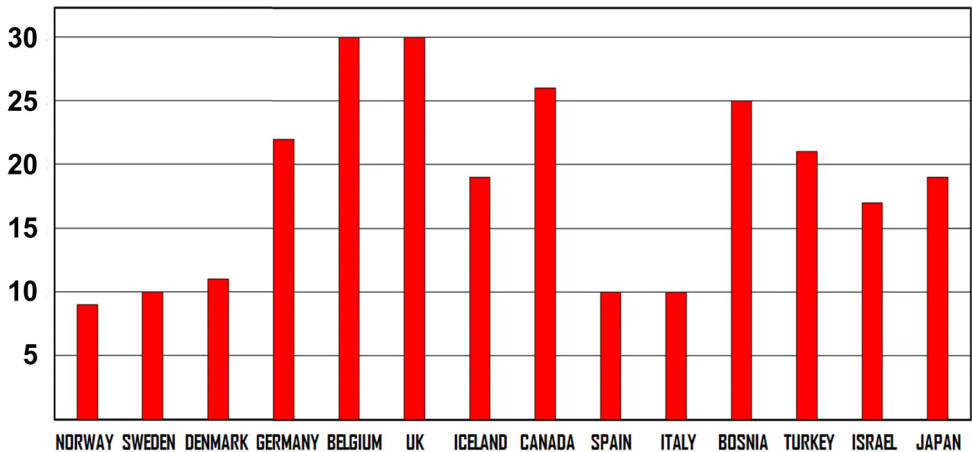


Fig. 2. Prevalence (%) of palmar fibromatosis in selected countries. Observe that the values of the original “Viking homelands” (Denmark, Norway, Sweden) have the same moderate prevalence (c.10%) as Mediterranean Spain and Italy, while some countries lacking Nordic ancestry (Bosnia, Turkey, Israel, Japan) have rather high values.

British Isles. In fact, there are written mentions and skeletal remains of Africans in Britain in both Roman and Viking times (Wells 1980; Green 2016; Seaman 2018). Moreover, there was a major raid with many captives in Morocco by Irish Vikings in 859 AD (Christys 2015). The event, which was probably not unique, is mentioned in old Christian and Moorish chronicles (Alfonso III de Asturias 1918 [c.900]; van Leeuwen & Ferre 1992 [1068]; Mac Firisigh 1860 [1000s]).

They afterwards crossed the Gaditanean [Cadiz] Straits ... and arrived in Africa, and there they fought a battle with the Mauritani ... with a great slaughter ... and they carried off a great host of them as captives to Erin, and these are the blue [black] men [of Erin] ... long indeed were these blue men in Erin (Mac Firisigh 1860 [1000s]: 161-163).

But we are not really claiming that the Romans and/or Vikings are to blame for spreading palmar fibromatosis from Africa to the British Isles. We believe that the disease may have long been present but undetected in the Old World (cf. McFarlane 2002). It would not have been that common when life expectancy was low and, moreover, it could have been confused with other hand-impairing ailments of the elderly (rheumatic arthritis, osteoarthritis, sarcopenia). The geographical distribution of the disease in the map of Figure 1 may be biased for similar reasons: low life expectancy and/or inadequate medical services outside the industrialized world. The latter is supported by recent African research (Sefean & Mwangi 2017) and the statement made by local physicians that the disease “*is actually not so rare in black people after all*” (Richard-Kadio et al. 2008:40).

Differences in medical cultures may also play a role. After having learned to identify palmar fibromatosis while studying Medicine in Europe or North America, the new physicians would return to their home countries to recognize the disease among their patients. This would explain the recent surge of palmar fibromatosis cases in unexpected non-Nordic populations. It is likely that future ancient DNA research will show the presence of the disease in a wider geographical and chronological scale.

SUMMARIZING REMARKS

1. A “benediction hand” deformity was observed in a mummified mature Theban man who lived in the earlier half of the first millennium BC.
2. The deformity was attributed to either ulnar palsy or palmar fibromatosis.

3. The latter alternative was preferred based on features resembling the characteristic fibrotic pads/chords on the palmar face.
4. The sex and age of the individual agree with the epidemiology of palmar fibromatosis, but Egypt falls outside its “traditional” geographical range.
5. Palmar fibromatosis is supposed to affect mainly elderly North European men – hence “Viking disease” – but recently it has been reported in populations with little or no Nordic ancestry.
6. It is likely that the hitherto known distribution of the disease is biased by inadequate medical services and/or low life expectancy in the developing world.
7. In any event, if the mummified Theban man suffered indeed from palmar fibromatosis, then it is the earliest known case of the disease.
8. This would push the existence of the disorder back by about 2000 years and place it geographically far from its assumed Nordic associations.
9. And if our diagnose is incorrect, then we are probably dealing with the earliest known case of ulnar nerve palsy.

ACKNOWLEDGEMENTS

The Monthemhat Project was the joint endeavor of several institutions: the Archaeological Museum of Catalonia, the General Hospital of Catalonia, the International University SEK, the Supreme Council of Antiquities of Egypt, and the Tübingen University. The work conducted by the anthropological team was made possible by the generous contribution of the Bonastre family, who was actively involved in the project in the person of Egyptologist Montse Rius, and Phillips Healthcare Spain, which provided the BV Pulsera device used in radiological examinations.

BIBLIOGRAPHY

ALFONSO III DE ASTURIAS (1918) [c.900]. *Crónica de Alfonso III*. Madrid, Sucesores de Rivadeneyra.

ANON. 1992. *Rediscovering Pompeii*. Roma, “L’Erma” di Bretschneider.

BAXARIAS, J. GARCIA-GUIXÉ, E., FONTAINE, V., NÚÑEZ, M., HERRERÍN, J. & DINARÈS, R. (2011). Paleopatología en la tumba del gobernador egipcio Monthemhat: los resultados definitivos. In: A.González Martín, O.Cambra-Moo,

J.Rascón Pérez, M.Campo Martín, M.Robledo Acinas, E.Labajo González, J.Sánchez Sánchez (eds.), *Paleopatología: ciencia multidisciplinar*, p.125-133. Madrid, Universidad Autónoma.

BERNDT, S. (2018). The hand gesture and symbols of Sabazios. *Opuscula*, 2: 151-168.

CHRISTYS, A. (2015). *Vikings in the south – voyages to Iberia and the Mediterranean*. London, Bloomsbury Academic.

CRAXFORD, S. & RUSSEL, P.G. 2016. Dupuytren's disease. *Surgery*, 34: 139-143.

DASENT, G.W. (2012). *Icelandic Sagas and Other Historical Documents Relating to the Settlements and Descent of Northmen in the British Isles 3. The Orkneyingers Saga*. Cambridge, Cambridge University Press.

DEGREEF, I & DE SMET, L. (2010). A high prevalence of Dupuytren's disease in Flanders. *Acta Orthopædica Belgica*, 76: 316-320.

FONTAINE, V. & GARCIA-GUIXÉ, E. (2010). Les mòmies de la cachette d'El-Assassif. *Projecte Monthemhat. Missió Arqueològica a Egipte*, p.55-93. Barcelona, Museu d'Arqueologia de Catalunya.

GARCIA-GUIXÉ, E., FONTAINE, V., BAXARIAS, J., NÚÑEZ, M., DINARÈS, R. & HERRERÍN, J. (2010): Estudio antropológico, paleopatológico y radiológico de las momias localizadas en el almacén número 4 de la Casa Americana (Al-Assassif, Luxor, Egipto): Proyecto Monthemhat 2009. *Revista Internacional d'Humanitats*, 20.4.

GOMAA, F. & MARTÍNEZ BABÓN, J. (2007): Consideraciones preliminares sobre los trabajos realizados en la Tumba de Monthemhat (Tt 34). *Revista Internacional d'Humanitats*, 12.

GREEN, C. (2016). A note on the evidence for African migrants in Britain from the Bronze Age to the medieval period. <https://www.caitlingreen.org/2016/05/a-note-on-evidence-for-african-migrants.html> (accessed 13.02.2018).

HINDOCHA, S., MCGROUTHER, D.A. & BAYAT, A. (2009). Epidemiological evaluation of Dupuytren's disease. Incidence and prevalence rates in relation to etiology. *Hand*, 4: 256-269.

ILLARREGUI, E. & RIUS, M. (2010). La tumba TT-34 de Luxor. *Projecte Monthemhat. Missió Arqueològica a Egipte*, p.15-22. Barcelona, Museu d'Arqueologia de Catalunya.

JAKOBSSON, Á. & CLARK, D. (2013). *The Saga of Bishop Thorlak*. London, Viking Society for Northern Research.

LECLANT, J. (1961). Montouemhat. Quatrième prophète d'Amon, prince de la ville. *Institut Français d'Archéologie Orientale, Bibliothèque d'Etude*, 35.

VAN LEEUWEN, A. & FERRE, A. (1992)[1068]. *Roads and Kingdoms: Albakrī, 'Ubayd 'Abd Allāh ibn 'Abd al Azis, Kitab almasālik walmamālik I. Qartāj, Aldār al' arabyya lilkitāb.*

MAC FIRBISIGH, D. (1860) [1000s]. *Annals of Ireland*. Dublin, The Irish Archaeological and Celtic Society.

MCFARLANE, R.M. (2002). On the origin and spread of Dupuytren's disease. *Journal of Hand Surgery*, 27: 385-390.

MCFARLANE, R.M., MCGROUTHER, D.A. & FLINT M.H. (eds) (1990). *Dupuytren's disease: Biology and treatment*. Edinburgh, Churchill Livingstone.

NÚÑEZ, M., PAAVOLA, K., GARCIA, E., BAXARIAS, J., DINARÈS, R., FONTAINE, V. & HERRERÍN, J. (2011). Old forgotten mummies from north and south. In: K.Salo & M.Niukkanen (eds) *Hautakaivaukset arkeologiassa*, p.92-105. Helsinki, Museovirasto.

O'DRISCOLL, S.W., HORII, E., CARMICHAEL, S.W. & MORREY, B.F. (1991). The cubital tunnel and ulnar neuropathy. *Journal of Bone Joint Surgery*, 73-B: 613-617.

PAYRAUDEAU, F. (2013): Généalogie et mémoire familiale à la Troisième Période intermédiaire: le cas de la statue Caire JE 37880. *Revue d'Égyptologie*, 64: 63-92.

RICHARD-KADIO, M., YEO, S., KOSSOKO, H., Allah, C-K., ASSI-DJE BI DJE, V. (2008). La maladie de Dupuytren. À propos de trois cas chez le Noir Africain. *Chirurgie de la Main*, 27: 40-42.

ROBERTSON, C. & SARATSIOTIS, J. (2003). A review of compressive ulnar neuropathy at the elbow. *Journal of Manipulative and Physiological Therapeutics*, 28.5.

SCOTT, K.R., SOMYREDDY, K. & KOTHARI, M.J. (2015). Entrapment neuropathies of the upper extremity. In: P.D.Donofrio (ed.), *Textbook of peripheral neuropathy* (E-book), Chapter 6. New York, Demosmedical.

SEAMAN, J. (2018). The mystery of Beachy Head Lady: A Roman African from Eastbourne. <https://museumcrush.org/the-mystery-of-beachy-head-lady-a-roman-african-from-eastbourne/> (accessed 22.06.2018).

SEFEANE, T.I. & MWANGI, P.N. (2017). Incidence of Dupuytren's disease in Africans: A report of 48 new cases and a literature review. *South African Orthopedic Journal*, 16.2: 50-53.

SORENE, E.D., RUBINRAUT-OPHIR, E. & GOODWIN E.R. (2007). Dupuytren's disease in Oriental Jews. *Journal of Hand Surgery (European Volume)*, 32: 543-546.

STEWART, J.D. (1987). The variable clinical manifestations of ulnar neuropathies at the elbow. *Journal of Neurology, Neurosurgery, and Psychiatry*, 50: 252-258.

WELLS, C. (1980). Discussion of human bones. *EAA Report*, 9: 247-314.

WERKER, P.M.N., DIAS, J., EATON, C., RICHERT, B. & WAERT, W. (2016). *Dupuytren Disease and Related Diseases - The Cutting Edge*. Cham: Springer (accessed 22.6.2018).

ZDILLA M.J. (2017). The Hand of Sabazios: Evidence of Dupuytren's Disease in Antiquity and the Origin of the Hand of Benediction. *The Journal of Hand Surgery (Asian-Pacific)*, 22: 403-410.

ZERAJIC, D. & FINSEN, V. (2004). Dupuytren's disease in Bosnia and Herzegovina. An epidemiological study. *BMC Musculoskeletal Disorders*, 5:10.