

OH NESPAMEDU! THE GOD ANUBIS HAS COME AND GRANTED YOU ETERNITY

M. Carmen Pérez-Die¹ and Javier Carrascoso Arranz²

¹ Museo Arqueológico Nacional
carmen.perezdie@cultura.gob.es

² Hospital Quirónsalud
javcarrascoso@hotmail.com

PÉREZ-DIE, M.C. AND CARRASCOSO-ARRANZ, J. (2021). Oh Nespamedu! The god Anubis has come and granted you eternity. *Canarias Arqueológica*, 22: 329-339. <http://doi.org/10.31939/canarq/2021.22.27>

Abstract. This article presents the anthropological, historical and religious studies of the mummy of Nespamedu, an Egyptian male who lived in the 3rd - 2nd century BC and was a priest of Imhotep and physician to the Pharaoh. The mummy was taken to the Hospital Quirónsalud Madrid to undergo a CT scan, under the agreement signed by the Hospital and the National Archaeological Museum, Madrid. Nespamedu is covered with five pieces of gilded cartonnage, decorated with religious scenes and inscriptions which

mention the god Anubis and the desire to achieve eternity.

In the CT scan a series of unique objects ornamenting the body of Nespamedu was observed among the wrappings, including a diadem, bracelets, a collar and sandals. A series of plaque-amulets was also revealed, decorated with Egyptian deities, all made of the same material as the cartonnage. This study has enabled a better understanding of some essential features of Egyptian funerary beliefs.

Keywords. Imhotep. Jewellery. Amulets. Inscriptions. Anthropological studies.

- Mummy of Nespamedu (Fig.1).

Inv. Number: I925/57/1 (Mummy). I925/57/2 - I925/57/6: gilded cartonnages.

Dimensions: 160 cm high; 38 cm wide.

Name of Father: *Pasenet*.

Name of Mother: *Ta-jwt-netcher, Lady of the house*.

Titles: Priest of Imhotep, Physician to the Pharaoh.

Chronology: Ptolemaic Period (300-200 BC). (Ptolemy II or Ptolemy III).

Age: Nespamedu died at c.50 years of age.

Provenance: Unknown. Perhaps Saqqara or Alexandria. This mummy was purchased from the Cairo Museum, Egypt.

The Mummy is currently exhibited in Room 35 of the National Archaeological Museum, Madrid.

I. HISTORY AND STUDIES

In May 1925 the mummy of Nespamedu arrived at the port of Barcelona in the steamship C. López y López and remained there for 3 months on account of bureaucratic problems. At the end of August, Ignacio Bauer donated the mummy to the National Archaeological Museum in Madrid. The Director of the Museum at the time, D. Jose Ramón Mélida, identified it as “the mummy of a female, the body covered by 5 gilded cartonnages with inscriptions and symbols”¹.

In 1954, a catalogue mentions the mummy of Nespamedu, with the information that the mummy was covered from head to foot with gilded cartonnages².

The mummy had been studied before the scan carried out in the Hospital Quirónsalud Madrid³. The most important radiological study was performed by Llagostera in 1978⁴.

¹ Expediente I925/57 Museo Arquelógico. Pons et al. (2018), 396-402. This publication presents all the documents concerning the Nespamedu mummy conserved in the Museum.

² Guía, 1954: 174.

³ Pérez-Die, M.C. (1978): 18-19. Pérez-Die, M.C. (1985): 25. Pérez-Die, M.C. (1991): 98. Pérez-Die, M.C. (2007): 28. Pérez-Die, M.C. (2015): 140-141. Pérez-Die, M.C., Pons Mellado, E. (2013): 116. Pérez-Die, M.C., Pons Mellado, E. (2017): 33. García Blasco y Padilla Montoya (1995): 18-19. Morales, A.J. (2014).

⁴ Llagostera E. (1978): 56-77.



Fig. 1. Mummy of Nespamedu covered with and without gilded cartonnages. Mummy unwrapped virtually.

An exhaustive analysis and control of the biodeterioration of the mummy of Nespamedu was carried out in 2011-12 in the Instituto de Patrimonio Histórico Artístico, as well as a radiological study of the mummy and restoration of the five gilded cartonnages⁵.

Under the agreements signed by the Hospital Quirónsalud Madrid and the National Archaeological Museum Madrid, the mummy was taken to the Hospital on the night of 5 - 6 June 2016 to undergo a CT scan.

More than 2700 axial images were generated. The 3D reconstruction tool was applied, and then the mummy was “unwrapped” virtually⁶:

The whole body is coated with a very dense resin, which has mostly accumulated in declining areas.

⁵ Herraiz et al. (2012): 7-29; Valentín, (2012): 121-123, fig. 20.

⁶ Pérez-Die, M. C. et al. (2018): 427.

On the axial plane, two layers of bandages were observed:

- a) An inner layer around the body and each upper and lower limb.
- b) An outer layer covering the whole body.

Each finger was individually bandaged.

2. ANTHROPOLOGICAL STUDIES

The brain was removed via the nostrils, breaking the ethmoidal cells, the weakest part of the brain. The skull was later filled with resins, with part of the brain or meninges remaining.

“Artificial eyes” made of wax were placed in the eye sockets.

The dental health of this male was poor, as was characteristic of the Egyptian population, with missing teeth, multiple cavities and apical abscesses at the root of the teeth. The surface of the molars was smooth, and the crowns were very worn as a result of the diet.

In the thoracic and abdominal cavities there were four cylindrical bundles of bandages, mixed with resins. These bundles may have contained the lungs, stomach, intestines and liver which were desiccated or possibly only bandages with no viscera inside them (Fig. 2).

The heart was not removed and was mixed with the resins. During the mummification process the heart was left inside the body as it is the main organ of the individual and in it laid the intelligence and will.

The muscles of the penis were also consumed by the natron and to give it a proper shape, it was filled with something similar to wood and resins.

No cause of death was established. Degenerative changes are present in the cervical and lumbar spine and two small consolidated rib fractures.

Obtaining all the data enabled, a three-dimensional reconstruction of the skull of Nespamedu was done from the CT images⁷ (Fig. 3).

The mummy is protected with five gilded cartonnages that completely cover the body. The name, titles and affiliation of the deceased, as well as a series of religious formulas translated by Dr. Morales, are inscribed on the cartonnages. Among the religious texts is the invocation to Anubis: “Oh Nespamedu! The god Anubis has come and granted you eternity”.⁸ The main parallels to the representations

⁷ Reconstruction by Juan Vila

⁸ Dunand, F. y Zivie-Coche, C. (1991).

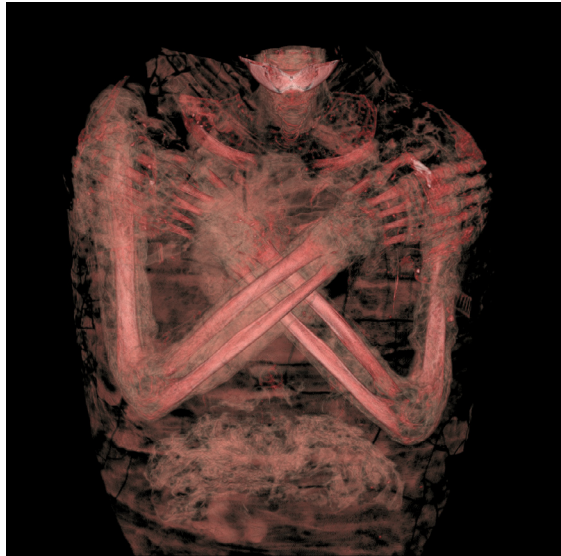


Fig. 2. Thoracic and abdominal cavities. Arms crossed over the chest.



Fig. 3. Three-dimensional reconstruction of the Skull of Nespamedu.

are found on the gilded cartonnages of Nespamedu. (fig. 6:8) The iconography is almost identical. A new scan of the cartonnages enabled us to conclude that the materials of the jewellery, amulets and cartonnages are the same and were made by the same artist.

3. JEWELLERY⁹

A series of jewels, amulets and the heart were placed in the interior of the mummy of Nespamedu (Fig. 4).

The jewels¹⁰ are a diadem, a *usekh* collar, bracelets and wristband, and sandal soles. The diadem represents a winged scarab with the solar disk, placed upside down. The scarab is the god Khepri, the symbol of resurrection and rebirth. This god is often represented rolling the solar disk across the sky. On the cartonnage, the representation of Khepri appears on the crown (Fig. 5).

N e s p a m e d u wears a *usekh* collar around his neck. This collar is one of the

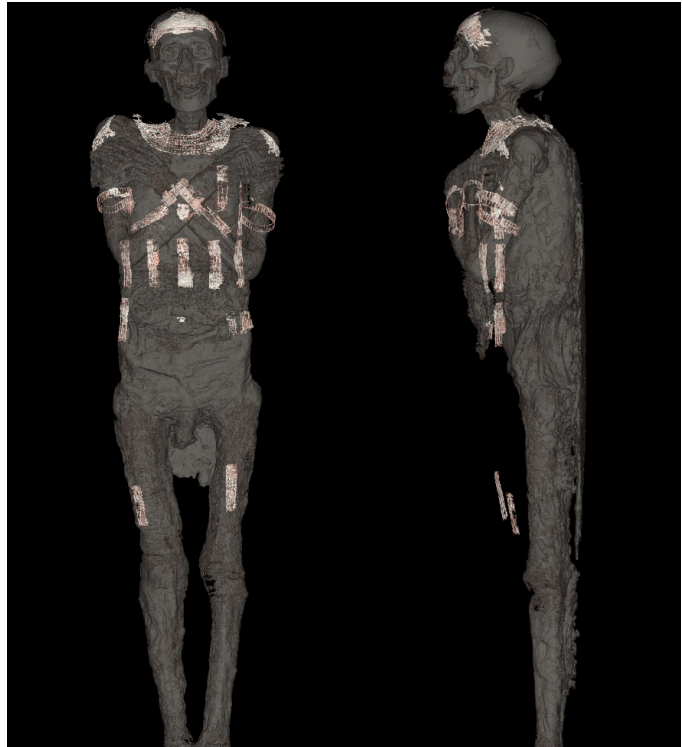


Fig. 4. Jewels, amulets and heart inside de Mummy. Front and profile.

⁹ Pérez-Die M.C. y Carrascoso Arranz, J. (2018): 429-452. VV.AA. (2018): 71-88.

¹⁰ Carol, N. (1990).

most characteristic in Egyptian jewellery and is usually topped with two falcon heads resting on the shoulders. It was used by the living and by the dead. It is also represented on the cartonnage.

The bracelets and wristbands ensure the immortality of the deceased. They can carry inscriptions, texts addressed to the deity, and spells destined to make the rights of the deceased prevail in the Afterlife.

The soles of the sandals worn by Nespamedu are the

same ones that appear on the cartonnages. Footwear in Egypt was a symbol of authority and economic power and, when embalming a person of high social status, sandals were placed in position for walking in the underworld.

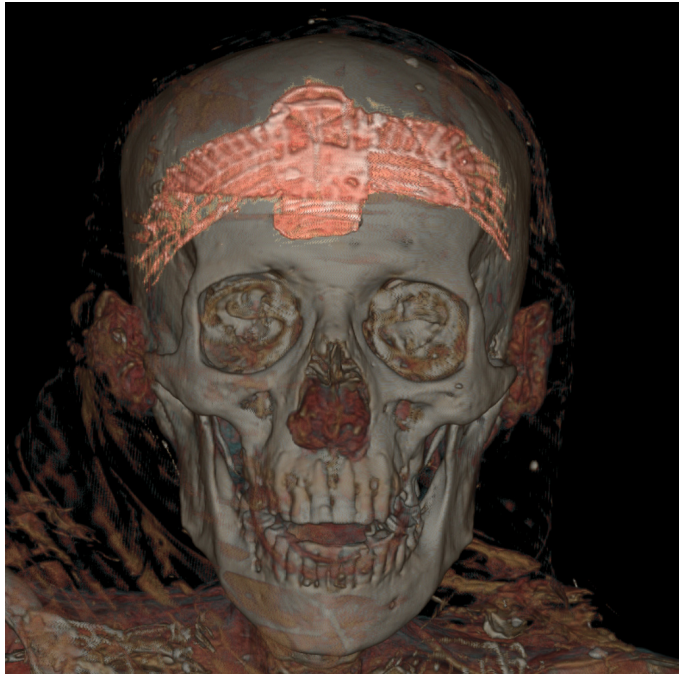

Fig. 5. Diadem with the representation of the God Khepri, the winged scarabs.

4. AMULETS. ICONOGRAPHICAL STUDIES (Fig. 6)

Inside the body of Nespamedu 12 amulet-plaques were also placed between the bandages with figures of the divinities, plus two *udjat* eyes and one heart, the seat of emotion, the key to the afterlife. The heart, was essential to surviving death in the nether world. The deities represented are the four sons of Horus in two series (eight in all), the mourners Isis and Nephthys, and the god Thoth (twice).

Two amulets plaques represent Isis and Nephthys as mourners. The scenes in which the goddesses appear are related to the ritual of mummification (Fig. 6:1-2). The deceased, assimilated to Osiris, was mourned by the goddesses Isis and




Fig. 6. Amulets – plaques (1-7) 6:1-2 Isis and Nephtys as mourners. 6:3 God Thot. 6:4-7 Four Sons of Horus. 6:4 Hapi. 6:5 Amset. 6:6 Duamutef. 6:7 Quebehsenuf. 6:8 Gilded cartonnage.

Nephthys, wife and sister respectively of Osiris, to whom all the deceased were assimilated. This whole scene is shown on the cartonnage and was linked to the mummification rite, with the deceased lying on his bed and assisted by Anubis (Fig. 6:8).

The god Thot is represented as an Ibis bird with a long beak, a mummy-like human body in profile and holding a staff (Fig. 6:3). He acted as judge in the dispute between the brothers Horus and Seth, healing the damaged eye of Horus. Thot, god of science and medicine is the ancestor of ophthalmology and the protective deity of ophthalmologists¹¹.

The four deities called "Sons of Horus" were also the covers of the four canopic jars, containers for the viscera after the mummification process (Fig. 6:4-7). Each one represents a specific divinity and has a different head. They protect each of the viscera of the mummy: Duamutef, with a jackal's head, for the stomach; Hapi, with a baboon's head, for the lungs; Amset, with a human head, for the liver, and Quebehsenuf, with a hawk's head, for the intestines.

The *udjat* represents the eye of a hawk. During the fierce struggle between Seth and Horus, Seth the evil god tore out the left eye of Horus, but it was healed and delivered to Horus by the god Thot. In the Hearst Papyrus it reads "I am Thot, the doctor of the eye of Horus". Thot and the *udjat* are closely related to the medical profession of Nespamedu, thus the choice of these amulets to be buried with him.

5. CONCLUSIONS

The title "Priest of Imhotep", is related to Nespamedu's profession as a physician. Imhotep was also a god of medicine who exercised in the Greek Asclepius in Saqqara, a sanatorium where he cured the sick who came from all over Egypt. Nespamedu must have used his medical skills in this sanatorium, as well as attending the Pharaoh as his personal physician.

Once the iconography on the cartonnages and the sheets has been fully analysed, we can verify that it responds to Nespamedu's express wishes to be accompanied by it in accordance with his titles and beliefs.

¹¹ Hurry, J.B. (1978). Derchain-Urtel, M.T. (1981). Wildung, D. (1977).

BIBLIOGRAPHY

ANDREWS, C. (1990). *Ancient Egyptian Jewellery* / London: British Museum Publications 208.

ANDREWS, C. (1994). *Amulets of Ancient Egypt*. London: Trustees of the British Museum.

DERCHAIN-URTEL, M.T. (1981). *Thot à travers ses épithètes dans les scènes d'offrandes des temples d'époque gréco-romaine*. Fondation Égyptologique Reine Elisabeth, Rites égyptiennes, 3. Bruxelles.

DUNAND, F., ZIVIE-COCHE, C. (1991). *Dieux et hommes en Égypte. 3000 a.C. – 395 après J.C.* Paris: Armand Collin.

GARCÍA BLASCO, A., PADILLA MONTTOYA, C. (coord.) (1995). "La momia de Nespamedu", Creencias y ritos funerarios. *Serie guías didácticas del MAN*. Tema I. Madrid, Fundación Caja Madrid y Museo Arqueológico Nacional: 18-19.

GUÍA (1954). *Guía de los Museos de España. Museo Arqueológico Nacional* Madrid: Tip de la Revista de Archivos, Bibliotecas y Museos.

HERRÁEZ, M.I., OROZCO, D., ACUÑA, M., GARCÍA RODRÍGUEZ, M.A., NAVARRO GASCÓN, J.V., ARTEAGA RODRÍGUEZ, A., SÁNCHEZ LEDESMA, A., ANTELO, T., BUESO, M., VALENTÍN, N., MONTERO, J., LLAGOSTERA, E., SÁNCHEZ, J.A. (2012). "La momia de Nespamedu. Estudio y proceso de intervención realizados sobre una momia egipcia de época ptolemaica", *Informes y Trabajos*, 8: 7-29.

HURRY, J. B. (1978). *Imhotep: The vizier and physician of King Zoser and afterwards the Egyptian god of medicine*. Chicago: Aris Publisher.

LLAGOSTERA, E. (1978). *Estudio radiológico de las momias egipcias del Museo Arqueológico Nacional de Madrid*. Monografías Arqueológicas, 5. Madrid.

MATHIESON, I. (2008). «En busca de Imhotep», *Revista de Arqueología*, 325, XXIX: 40-43.

MORALES, A.J. (2014). «La momia de Nespamedu (Museo Arqueológico Nacional)», *101 Obras maestras: ciencia y arte en los museos y bibliotecas de Madrid*. Madrid: CSIC. Disponible en: <<http://www.101obrasmaestras.com/en>>.

PÉREZ-DIE, M.C. (1978). «Historia de las Momias egipcias del Museo Arqueológico Nacional», E. Llagostera, *Estudio de las momias egipcias del Museo Arqueológico Nacional*. Madrid: 12-19.

PÉREZ-DIE, M.C. (1985). *Egipto. Guía didáctica del Museo Arqueológico Nacional*, Madrid.

PÉREZ-DIE, M.C. (1991). *Guía General. Egipto y Próximo Oriente*: 90-112.

PÉREZ-DIE, M.C. (2007). «Egipto, Nubia y Oriente Próximo. Colecciones del Museo Arqueológico Nacional, 25-29. Catálogo de exposición. Madrid.

PÉREZ-DIE, M.C. (2015). «La momia de Nespamedu» *Egipto, Nubia y Próximo Oriente. 75 obras seleccionadas de la Colección permanente del Museo Arqueológico Nacional*. Madrid: Ministerio de Educación, Cultura y Deporte. Palacios & Museos: 140-141.

PÉREZ-DIE, M.C., PONS MELLADO, E. (2013). *El Nilo: Egipto y Nubia*. Museo Arqueológico Nacional. Guía. Madrid: Ministerio de Educación, Cultura y Deporte: 110-119: 116.

PÉREZ-DIE, M.C., PONS MELLADO, E. (2017). *Egipto, Nubia y Oriente Próximo Antiguo*. Cuadernos del MAN, 3.

PÉREZ-DIE, M.C., CARRASCOSO ARRANZ, J. (2018): "Que ves? Cosas maravillosas" *Boletín del Museo Arqueológico Nacional*, 37: 429-452.

PÉREZ-DIE, M.C.; MORALES, A.; MARTÍNEZ DE VEGA, V.; CARRASCOSO, J. y BADILLO, S. (2018). «Preservar a sus muertos de la muerte. La momia egipcia de Nespamedu en el Museo Arqueológico Nacional». *Boletín del Museo Arqueológico Nacional*, 37: 409-428.

PONS MELLADO, E., BADILLO, S., CARRASCOSA, J., MARTÍNEZ DE VEGA, V. (2018). «Momias humanas egipcias. Un viaje en el tiempo, del país del Nilo al Museo Arqueológico Nacional», *Boletín del Museo Arqueológico Nacional*, 37: 391-408.

VALENTÍN, N. (2012). «Análisis y Control del Biodeterioro. A las plagas les gustan las momias». *Momias, Manual buenas prácticas para su preservación*. Madrid, Ministerio de Educación, Cultura y Deporte: 99-131.

VALENTÍN, N., MONTERO, J. (2011). "Desinfección y desinsectación de una momia egipcia de la necrópolis de Saqqara, procedente del Museo Arqueológico Nacional. Informe interno del IPCE. Inédito.

WILDUNG, D. (1977). *Imhotep and Amenhotep: gottwedung im alter Agypte*. *Muncher Agyptologischen Studien*, 36. Munchen: Deutscher Junstrelrag.

VV.AA. (2018). "Nespamedu, cuando una momia se convierte en estrella" *Viaje al Interior de las momias. Autopsia virtual a momias milenarias*. Madrid: 71-88.

